

MAJOR REVIEW

Diving and Hyperbaric Ophthalmology

CAPTAIN FRANK K. BUTLER, JR., MD

Department of Ophthalmology, U.S. Naval Hospital, Pensacola, Florida

Abstract. Exposure of the human body to ambient pressures greater than that at sea level may result in various disorders, some of which have ocular manifestations. Additionally, some eye disorders and postoperative states may be adversely affected by the underwater environment or other hyperbaric exposures. The prevalence of recreational, military, and commercial diving, as well as the medical use of hyperbaric oxygen therapy, requires that ophthalmologists be familiar with the effects of the hyperbaric environment on the normal and diseased eye. The ophthalmology and diving medical literatures were surveyed for publications relating to the ophthalmic aspects of diving and hyperbaric exposures. Underwater optics, underwater refractive correction, and ophthalmic aspects of a fitness-to-dive evaluation are summarized. The evaluation and management of ocular manifestations of decompression sickness and arterial gas embolism are reviewed and guidelines for diving after ocular surgery are proposed. (*Surv Ophthalmol* 39:347-366, 1995)

Key words. arterial gas embolism . contact lenses . decompression sickness . diving . glaucoma . hyperbaric oxygen . ocular barotrauma . ophthalmic surgery . oxygen toxicity . photorefractive keratectomy . radial keratotomy

The human eye normally exists in a world where it is exposed to an ambient pressure which is the result of the combined and equally distributed weight of all of the gases in the earth's atmosphere. At sea level, this pressure is described as one atmosphere absolute (ATA). Exposure to increased ambient pressure entails a new set of potential ocular disorders and raises new issues in the management of common ophthalmic medical and surgical conditions.

The popularity of recreational SCUBA diving continues to increase and the value of hyperbaric oxygen therapy as a treatment modality is being recognized in a growing number of disorders. As more and more individuals participate in such activities, the likelihood that ophthalmologists will encounter patients with diving-related problems will grow. Glaucoma patients will want to know whether or not the increased pressure ex-

perienced while diving could cause acceleration of their optic nerve damage. Radial keratotomy patients will ask if and when it is safe to dive after their surgery. Contact lens wearers will want to know if they can dive in their lenses and which lenses are best tolerated in the underwater environment.

Many of these issues are not well addressed in the ophthalmic literature, and this review was undertaken to examine these topics. Medline searches with the key words noted above (and others, as seemed appropriate) were performed and were supplemented with an issue-by-issue review of the major journals in ophthalmology and diving medicine for the last six years. Standard texts in both ophthalmology and diving medicine were reviewed as well as research reports from U.S. Navy hyperbaric laboratories. Essentially all references identified which dealt

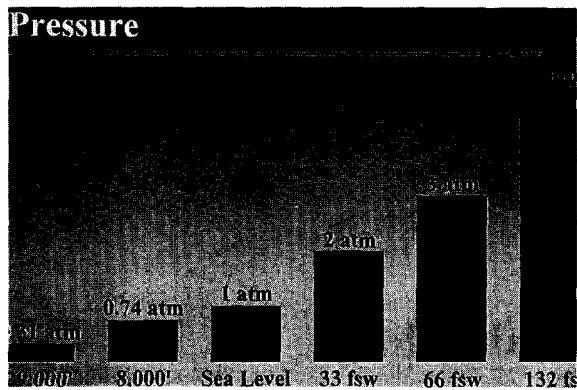


Fig. 1. Ambient absolute pressures at different depths and altitudes. (Photograph courtesy of Dr. Richard Vann)

specifically with the ophthalmic aspects of diving and hyperbaric exposures were included. Additional references were added as necessary to help answer diving-related questions on various ocular diseases and post-operative states.

I. Hyperbaric Terminology and Physics

A review of basic diving terminology and physics will help to acquaint ophthalmologists with some of the pertinent aspects of hyperbaric exposures. At sea level, the body is exposed to one ATA of pressure. This magnitude of pressure may be expressed in other units. For comparison, 760 millimeters of mercury (mm Hg), 33 feet of sea water (FSW), and 14.7 pounds per square inch (psi) all denote a pressure equivalent to one ATA. The normal atmospheric pressure of 1 ATA is often used as a reference point from which other pressures are measured. When one states that the intraocular pressure (IOP) is 15 mm Hg, one means that the IOP is 15 mm Hg more than the surrounding environment. In point of fact, the absolute pressure inside the eye is 775 (760 ± 15) mm Hg. The IOP that we measure with the tonometer is therefore a "gauge" pressure, meaning that the pressure displayed is the actual pressure minus the constant 1 ATA of atmospheric pressure.

An analogy using a diver helps to illustrate the point. The depth gauge of a diver on the surface will read "0," but the ambient pressure to which the diver is exposed is 1 ATA. An ambient pressure of 0 mm Hg is encountered only in space beyond the influence of planetary atmospheres. At 33 feet under the water, the depth gauge will

read 33 FSW, but the diver is at an absolute pressure of 2 ATA. Another way of expressing this relationship is to say that the absolute pressure in ATAs is the gauge pressure plus one atmosphere. When using depth in feet of sea water, this is expressed by the formula $ATA = (\text{depth} + 33)/(33)$. The absolute pressures at various depths and altitudes are depicted in Fig. 1.

The response of the body to changes in ambient pressure depends on the anatomy of the organ system in question. A fluid-filled space or a solid organ will not change in size as pressure changes, since fluids are not compressible. A gas-filled space with elastic walls, however, will change in size according to Boyle's law. This law states that the volume of a certain quantity of gas is inversely proportional to the absolute pressure (the product of pressure and volume is a constant). For example, a balloon with a volume of one cubic foot of air on the surface (1 ATA) would shrink to a volume of one-half cubic foot if taken to a depth of 33 FSW (2 ATA) and to one-fourth of a cubic foot at 99 FSW (4 ATA). The effect of increasing ambient pressure on volume is illustrated in Fig. 2.

In most tissues within the body, however, the spaces within which gas is located (i.e., lungs, middle ear) have only a limited capability to change their volume. This presents no problem as long as the quantity of gas within the space is allowed to change to compensate for changes in pressure. This is the basis for teaching divers to clear their ears (add gas to the middle ear cavity) on descent and to exhale on ascent. If this equalization is not accomplished, the tissues adjacent to the gas space may be damaged by stretching or tearing, as occurs with an "ear squeeze" or pulmonary alveolar rupture. Damage to tissues caused by changes in pressure is called barotrauma.

A second physical law of importance in diving is Henry's law. This law states that the amount of gas that will dissolve in a liquid at a given temperature is directly proportional to the partial pressure of that gas. This law is central to understanding the pathophysiology of decompression sickness. As a diver descends in the water column, the increased pressure causes more nitrogen to enter into solution in his tissues than was present at the surface. If enough nitrogen enters into solution and the diver then returns to the surface too quickly, the excess inert gas will not have a chance to be eliminated gradually through the lungs. The nitrogen will then come

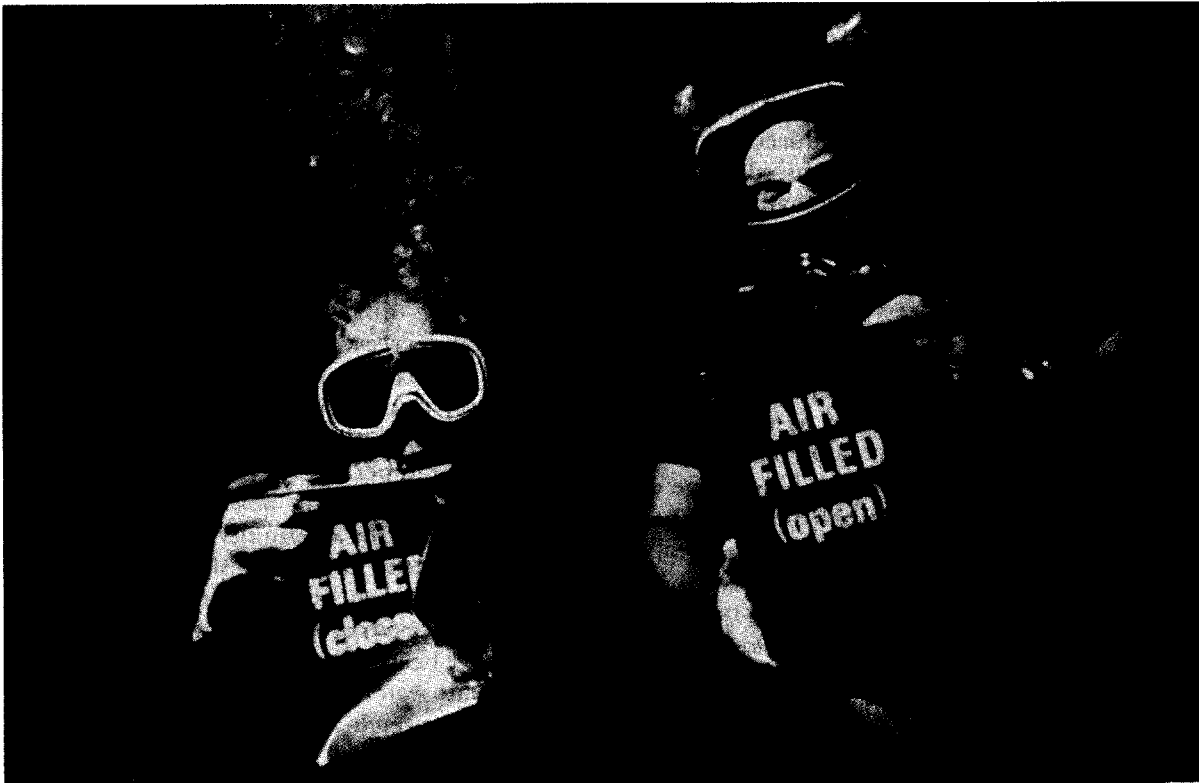

Fig. 2. Boyle's law in action: the mechanism of barotrauma. The can on the right was open on the bottom to allow water to enter and equalize the pressure in the gas space on descent. The can on the left was closed and pressure equalization was achieved by collapse of the can. (Photograph courtesy of Dr. Richard Vann)

out of solution and a gas phase (bubbles) will form in the blood and body tissues. These bubbles may result in the clinical entity known as decompression sickness (DCS). This disorder will be discussed further in Section VI.

II. Types of Hyperbaric Exposures

Recreational SCUBA diving is the most common type of hyperbaric exposure. This pastime has undergone an explosive growth in popularity over the last decade. The Diver's Alert Network (DAN) located in Durham, N.C., is the best known civilian referral facility in the United States for diving medical emergencies. DAN statistics indicate that there are over two million active recreational SCUBA divers in the USA. A great deal of diving is also done for military and commercial purposes.

Hyperbaric exposures other than diving are also encountered. Hyperbaric oxygen (HBO) therapy in which a patient is compressed in a dry chamber to pressures equivalent to depths of 30-60 FSW and given 100% oxygen to breathe is now being used as an adjunctive treatment mo-

dality for a growing number of disorders, including decompression sickness, arterial gas embolism, carbon monoxide poisoning, clostridial myonecrosis, crush injuries, diabetic leg ulcers, failing skin grafts, refractory osteomyelitis, thermal burns, necrotizing soft tissue infections, and osteoradionecrosis.^{31,99}

Compressed air is commonly used in underwater construction and tunneling projects to prevent the entrance of water into the working space. Personnel in these hyperbaric environments are also at risk from decompression sickness and the other dysbaric conditions described in the sections to follow.

III. Underwater Optics

A. LIGHT ATTENUATION

As light travels through water, it is attenuated by both scattering and absorption.⁵⁶ With increasing depth, the amount of light decreases and the water becomes progressively darker. Even in the clearest ocean water, only about 20% of incident light reaches a depth of 33 FSW and only 1% reaches 260 FSW." In clear water, suffi-

cient light for unaided vision is present during the day to a depth of approximately 400 FSW.⁹⁰ If, however, the water contains impurities, such as silt, algae, or chemical pollution, the amount of light transmitted is greatly reduced. In very turbid water, visibility may be reduced to a distance of a foot or less even at very shallow depths in bright sunlight.

B. COLOR PERCEPTION

Perception of color changes underwater with increasing depth because different wavelengths of light are selectively absorbed as visible light passes through water. Clear water has a maximum transparency to light in the blue range of the spectrum with a wavelength of 480 nanometers." Light of longer wavelengths is absorbed first, so red colors disappear quickly as depth increases. Red colors are usually not seen at depths below 30 feet and yellow colors disappear around 75 feet. At depths below 100 feet, only blues and greens remain.⁹⁰ Red objects are perceived as black." This effect may be reversed temporarily by the introduction of artificial light, such as in underwater flash photography, which allows objects to be photographed in their actual color at depth.

C. REFRACTIVE CHANGES

Refractive changes underwater may be illustrated by two situations. When a diver is without a face mask and has his or her eyes open underwater, the refractive power of the eye changes dramatically. The air-cornea interface is changed to a water-cornea interface. The refractive power of this interface is determined by the formula $(N_2 - N_1/r)$ where N_1 is the refractive index of air or water, N_2 is the refractive index of the cornea, and r is the radius of curvature of the cornea in meters. For air, this equation becomes $(1.37 - 1.00)/(0.008)$ or 46 diopters. In water, the equation changes to $(1.37 - 1.33)/(0.008)$ or 5 diopters. This loss of refracting power causes an induced hyperopia and blurring of underwater vision.

When a facemask is worn, the resulting air space restores the air/cornea interface to the front corneal surface. This eliminates the induced hyperopia. In this case, however, light traveling toward the eye will be refracted away from the normal as it exits the water medium and enters the air space of the face mask. This causes the object of regard to be magnified by approximately 30% and to appear closer than it actually is.^{27,100}

D. VISUAL FIELD

The sides of the face mask cause a significant reduction in the diver's visual field." The normal horizontal visual field encompasses almost 180 degrees. This field is reduced to approximately 85 degrees with a standard face mask." Vertical fields are also decreased; the decrease in the inferior visual field is probably of the greatest functional significance, since this may result in divers experiencing difficulty in seeing their equipment. The decrease in visual field is reduced by changes in mask design which bring the face plate closer to the eyes. The use of clear plastic plates in the side pieces may also help to reduce the decrease in peripheral vision imposed by the face mask. This design, however, results in an interruption in the continuity of the horizontal visual field at the junction of the side plates and center plate which may be disconcerting. The visual fields produced by different types of face masks have been described," but the presence of an adequate watertight seal and a comfortable fit probably outweigh any other considerations in selecting a face mask.

IV. Underwater Refractive Correction

For ametropic individuals who must consider the refractive options available to them in the underwater environment, the two primary choices are contact lenses and prescription face masks.

A. CONTACT LENSES

If contact lenses are to be used, soft contact lenses are the preferred type for diving.^{20,25,29,54,66} Hard (PMMA) contact lenses have been shown to cause corneal edema during decompression and after dives.^{87,88,112} These changes are caused by the formation of nitrogen bubbles in the precorneal tear film which interfere with normal tear film physiology and result in epithelial edema. Bubble formation would be expected to be more common during dives with significant decompression stress. The presence of a 0.4 mm fenestration in the center of a PMMA lens has been reported to prevent bubble trapping and the resultant corneal edema.^{29,88} Although the increased gaseous diffusion properties of rigid gas permeable contact lenses theoretically decreases the probability of bubble formation in the tear film, use of these lenses while diving has also been demonstrated to cause bubble formation in the tear film with secondary corneal epithelial disruption.⁸⁹

Corneal edema was not observed in two studies which examined the use of soft contact lenses

while diving.^{20,88} The most frequent complication of contact lens use in diving is loss of the lens,^{54,57} but the larger size and more secure fit of soft contact lenses reduce the frequency of this occurrence.⁴¹ The risk of lens loss can be minimized by ensuring a good seal on the face mask. Should the mask leak or become displaced during the dive, narrowing of the palpebral fissure may help to decrease the chance of a contact lens floating off of the surface of the eye.⁵⁴ If spherical soft contact lenses are unsatisfactory because of significant astigmatism, a toric soft contact or a fenestrated rigid gas permeable lens may be required to provide satisfactory acuity.

B. CORRECTIVE FACE MASK LENSES

Prescription ground face mask lenses provide another refractive alternative. A face mask with corrective lenses bonded onto the face plate of the mask is also a possibility, but may present problems with eventual erosion of or bubble formation in the bonding substance used. When considering the purchase of an expensive prescription face mask, however, one needs to be mindful of the corollary of Murphy's law which applies to diving: "Weight belts always fall on the face masks with prescription lenses."

V. Ocular Barotrauma

The eye is normally filled with the non-compressible aqueous and vitreous humors and solid tissues and is therefore protected from barotrauma. Once a mask is placed over the face, however, a different circumstance exists. The face mask creates an air-filled space of which the eyes and ocular adnexae form part of one wall. As the diver descends, if he or she does not expel gas through the nose into the face mask, a relative negative pressure develops in this space. As the pressure differential increases, the eyes and ocular adnexae are drawn toward this space. Marked lid edema and ecchymosis as well as subconjunctival hemorrhage may result as tissues and blood vessels are disrupted by this distention. The results may be disconcerting to the diver, but typically resolve without sequelae. In severe cases of ocular barotrauma, such as may occur when an unconscious diver sinks a significant distance in the water column, more serious injury including hyphema may be seen (Personal communication, CDR Clint Fletcher, Pensacola, FL). Subperiosteal orbital hemorrhage has also been reported as a sequela of barotrauma.⁴ Overpressurization of the face mask as a diver returns to the surface is not a problem since the

excess gas volume generally escapes without incident.

Barotrauma will also occur in patients who dive with intraocular gas bubbles in the anterior chamber or vitreous cavity. Pressure-induced changes in the volume of this bubble may result in retinal, uveal, or vitreous hemorrhage, as well as partial collapse of the globe. One patient who attempted to dive while an iatrogenic bubble was still present in the eye after a gas-fluid exchange had been performed during vitreoretinal surgery noted the immediate onset of very severe eye pain upon descent and quickly aborted his dive (Personal communication, Dr. Tim Peterson, San Diego, CA). Patients with intraocular gas should not be allowed to dive as long as any of the bubble remains in the eye.

The need to add extra gas to the face mask air space during descent makes it clear that swim goggles, which cover only the eyes and not the nose, should never be used for diving. Ocular barotrauma is inevitable with these goggles if the diver descends more than several feet under the surface.

VI. Decompression Sickness

A. PATHOPHYSIOLOGY

When the body experiences a rapid reduction in ambient pressure, inert gas dissolved in the tissues may come out of solution as bubbles. These bubbles may form in the venous blood, in the musculoskeletal system, or in other body tissues. When these bubbles result in clinical signs or symptoms, the condition is called decompression sickness (DCS).

Adherence to published decompression tables reduces the risk of DCS, but does not eliminate it entirely. Many cases of DCS have been reported in divers who have been decompressed in strict compliance with published tables. The incidence of DCS for the commonly used U.S. Navy air decompression tables is approximately 1.25%.¹⁰⁷

Because the presenting symptoms and treatment of decompression sickness and arterial gas embolism resulting from pulmonary barotrauma (covered in the next section) may be very similar, the term "decompression illness" has been proposed to describe both disorders.⁴ Modifiers are added to this term to describe the evolution of signs and symptoms, the organ system affected, the length of time after the dive that symptoms began, the inert gas burden, and the level of suspicion of pulmonary barotrauma. The degree to which this new terminology will eventually replace the existing classification is uncer-

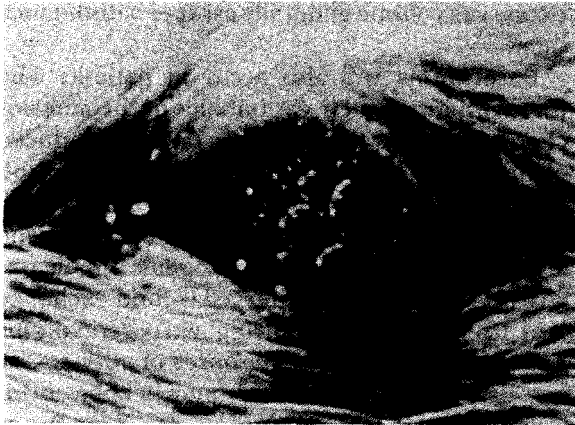


Fig. 3. Gas bubbles in the eye of an experimental animal exposed to decompression stress. (Photograph courtesy of Dr. Richard Vann)

tain at present, but it is currently encountered in some diving medical texts and journal articles.

B. SYSTEMIC MANIFESTATIONS

Decompression sickness is a multisystem disease. Limb pain is the most common complaint in DCS,^{33,38,107} with pain in the elbow, shoulder, hip and knee joints being the most prevalent sites. The skin may be involved, displaying a mottled appearance known as "cutis marmorata." Bubbles in the lymphatic system may result in regional lymphedema. Cases of decompression sickness limited to musculoskeletal, skin, or lymphatic manifestations are often referred to as Type I DCS. More severe cases may involve the brain, the spinal cord, or the cardiopulmonary system.* Neurologic manifestations may include sensory deficits, hemiplegia, paraplegia, paresthesias, loss of consciousness, cranial nerve palsies, and peripheral neuropathies.¹⁰¹ Possible cardiopulmonary effects include massive pulmonary gas emboli or myocardial infarction. Decompression sickness with neurologic or cardiopulmonary symptoms is often referred to as Type II DCS.

The presenting symptoms of DCS are influenced by the depth and bottom time of the dive, the inert gas breathed, the adequacy of decompression, and the delay to presentation. Lam and Yau reported 793 cases of DCS during a compressed air tunneling project in Hong Kong harbor. All cases but one in this series were Type I. The US Navy Diving Manual notes that the majority of DCS cases involve musculoskeletal pain." Even relatively high-risk experimental dive series conducted by the Navy to develop

new decompression tables and decompression computer programs were reported by Thalmann et al to have a predominance of Type I symptoms, with 106 cases of Type I as compared to 37 cases of Type II DCS.⁹⁴⁻⁹⁷ In contrast, reports of DCS in recreational divers and diving fishermen note a higher incidence of more serious symptoms. Kizer published a series of 50 cases with approximately half of the cases being from each of these two groups and noted 24 patients with Type 1 and 26 patients with Type II DCS.⁵⁸ Another study reported 58 cases of DCS in diving fishermen in Singapore."* These cases involved significant delays to recompression and had a much higher incidence of serious cases than the previous reports with 47 out of 58 patients experiencing Type II symptoms.

C. OPHTHALMIC MANIFESTATIONS

Ocular involvement in DCS was first noted in 1670 by Sir Robert Boyle when he observed gas bubbles in the anterior chamber of the eye of a viper which had been experimentally exposed to increased pressure.¹⁴ Anterior chamber bubble formation has also been reported during altitude exposures.³⁶ Fig. 3 shows a rat with this phenomenon. Ocular manifestations of DCS are relatively infrequently noted in the ophthalmic literature," but there are additional reports in the diving medical literature.^{15,23,33,49,81,92,106} Signs and symptoms described include nystagmus, diplopia, visual field defects, scotomas, homonymous hemianopias, orbicularis oculi pain, cortical blindness, convergence insufficiency, optic neuropathy and central retinal artery occlusion. The incidence of ocular symptoms in patients with DCS was found to be 7% and 12% in two large series.^{81,92} These signs and symptoms are summarized in Table 1.

Fluorescein angiography studies of divers have documented retinal pigment epithelial abnormalities indistinguishable from those seen in eyes with choroidal ischemia. These changes were attributed to decompression-induced intravascular gaseous microemboli." The incidence of these lesions was directly related to the length of diving and a history of decompression sickness. No divers suffered a loss of visual acuity from these abnormalities, but the paper notes that the long-term effects of this phenomenon remain to be studied. This report awaits confirmation from additional studies with age-matched controls.

Decompression sickness may also result when an individual without a previous hyperbaric ex-

posure is suddenly exposed to a decrease in pressure. One study of altitude DCS found that ophthalmic manifestations were the most common neurologic presentation observed.²³ Altitude DCS presenting as optic neuropathy has been reported.¹⁷ The risk of DCS may be increased if an altitude exposure is undertaken after diving without allowing an appropriate time interval to pass so that residual excess gas in solution has a chance to equilibrate at one atmosphere.

D. TREATMENT

Decompression sickness is treated with recompression to 60 FSW or deeper and hyperbaric oxygen breathing. In the USA, this therapy is usually guided by a Navy Treatment Table.¹³ These tables are very effective, especially when recompression therapy is begun promptly.¹³ Ophthalmologists seldom encounter this disease in an acute setting because most divers know to seek recompression therapy for signs or symptoms of DCS. Since treatment generally results in resolution of all symptoms, most patients with visual symptoms prior to treatment are asymptomatic following recompression treatment and are not referred to ophthalmologists.¹⁴ Should an ophthalmologist encounter a patient with visual disturbances compatible with DCS in an acute setting following a hyperbaric exposure, the patient should be referred to the nearest available recompression chamber and diving medicine specialist on an emergent basis, since DCS may increase rapidly, in severity if not treated. Physicians unsure of the location of the nearest diving medicine specialist or recompression chamber should call the Divers Alert Network at I-919-684-81 11.

Incomplete response to treatment, or a recurrence of symptoms following treatment may bring the patient with ocular DCS to the ophthalmologist on a less emergent basis. These patients should be managed in conjunction with a diving medicine specialist. Recompression therapy and hyperbaric oxygen should be administered even when presentation is delayed, since such treatment may be successful despite delays of up to several weeks.¹⁷

VII. Arterial Gas Embolism

A. PATHOPHYSIOLOGY

Arterial gas embolism (AGE) is another disorder in which dysbaric intravascular bubble formation may occur. The pathophysiology of this disorder is different, however, in that the bubbles in AGE typically originate not from inert

TABLE 1

Ocular Manifestations of Decompression Sickness

1. Nystagmus
2. Diplopia
3. Visual field defects
4. Scotoma
5. Homonymous hemianopia
6. Orbicularis oculi pain
7. Cortical blindness
8. Convergence insufficiency
9. Central retinal artery occlusion
10. Optic neuropathy

gas supersaturation, but from pulmonary barotrauma of ascent. This barotrauma results in rupture of the alveoli with gas bubbles entering the pulmonary venous system where they are carried to the heart and from there to the systemic circulation.

B. SYSTEMIC SYMPTOMS

Most symptoms in this disorder are localized to the cerebral circulation, although cardiac arrest may result from embolization of the coronary vessels. The classic presentation of arterial gas embolism is the sudden onset of unconsciousness within minutes of reaching the surface after a dive; other possible presentations include hemispheric motor and/or sensory deficits, confusion, and convulsion. Peripheral neuropathies and musculoskeletal pain are not seen with AGE.

C. OPHTHALMIC SYMPTOMS

Retrochiasmal defects such as hemianopias or cortical blindness are potential ocular manifestations of cerebral AGE,⁴⁷ and CRAO may result from gas emboli in the ophthalmic or central retinal artery.

D. TREATMENT

Management is similar to that for DCS, with emergent recompression and hyperbaric oxygen therapy indicated in all cases.

VIII. Other Causes of Decreased Vision after Diving

Decompression sickness and arterial gas embolism should be considered whenever vision is acutely decreased after diving because of the possible emergent need for recompression therapy. Other disorders, however, may also affect vision after a dive.

The possibility of corneal edema resulting from the formation of gas bubbles under PMMA

TABLE 2

Causes of Acutely Decreased Vision after Diving

-
1. Decompression sickness
 2. Arterial gas embolism
 3. Displaced contact lens
 4. Anti-fog keratopathy
 5. Ultraviolet keratitis
 6. Corneal edema resulting from bubbles under PMMA or rigid gas permeable contact lenses
 7. Contact lens adherence syndrome
-

and rigid gas-permeable contact lenses has been discussed previously. A soft contact lens wearer who complains of blurred vision after a dive should be checked to ensure that the lens has not been lost or displaced.

Another possible nondysbaric cause of decreased vision following a dive is an epithelial keratopathy induced by chemical agents used to reduce face mask fogging. Fogging of face masks is a common problem during diving. The time-honored application of saliva to the interior surface of the mask reduces but does not eliminate this problem. This led to the development of commercial antifog agents designed to be applied to the inside surface of face masks. These preparations may contain volatile compounds potentially toxic to the corneal epithelium such as glycols, alcohols, surface-active agents, and phenol derivatives. Exposure to these compounds may result in blurred vision, photophobia, tearing, and blepharospasm which presents shortly after the dive.¹¹³ Slit-lamp examination typically reveals a diffuse superficial punctate keratopathy. Development of this condition commonly results from improper use of the antifog agent, specifically an overly generous application of the agent and a failure to rinse the mask before use.

Contact with sea water can cause soft contact lenses to become tightly adherent to the cornea.⁵⁴ Individuals who wear this type of lens may experience recurrent mild ocular irritation and blurring of vision after dives as a result of this phenomenon. Symptoms are usually relieved with a few drops of isotonic artificial tears.

Ship husbandry and underwater construction commonly require the performance of welding while diving. Failure to use appropriate ultraviolet radiation protection may result in an ultraviolet keratitis. A history of welding, eye pain, and photophobia, as well as typical findings on slit-lamp examination will usually make this diag-

nosis apparent. Table 2 provides a summary of possible causes of an acute decrease in vision following a dive.

IX. Central Nervous System Oxygen Toxicity

A. PATHOPHYSIOLOGY

Although hyperbaric oxygen therapy is of great benefit in the treatment of DCS, AGE, and other disorders, its use is not without hazard. Oxygen at high partial pressures may have a number of adverse effects. Even in normoxic conditions, oxygen metabolism produces superoxide anions and other potentially harmful radicals. These radicals are removed by superoxide dismutase and other cellular defense mechanisms. In hyperoxic conditions, these defense mechanisms may be overwhelmed and oxygen toxicity may ensue. The entity of pulmonary oxygen toxicity is well known to most physicians and may result when patients receive supplemental oxygen therapy for extended periods of time, even at partial pressures less than one ATA. Manifestations of pulmonary oxygen toxicity include pleuritic chest pain, cough, and decrease in vital capacity. If oxygen administration is not discontinued, a life-threatening Adult Respiratory Distress Syndrome-type picture may ensue. At partial pressures of oxygen above 1.2 ATA, the onset of central nervous system oxygen toxicity may precede the development of pulmonary toxicity. The likelihood of CNS oxygen toxicity increases exponentially with increases in the partial pressure of oxygen and limits the therapeutic use of oxygen to partial pressures of 2.8 ATA and below.

B. SYSTEMIC MANIFESTATIONS

The use of hyperbaric oxygen therapy in the treatment of a growing number of clinical disorders increases the likelihood that ophthalmologists may encounter questions about the ocular manifestations of CNS oxygen toxicity. With the current use of oxygen-enriched oxygen gas mixtures (nitrox) for sport SCUBA diving, CNS oxygen toxicity may also be encountered in this setting. Common systemic symptoms of CNS oxygen toxicity include muscle twitching, tinnitus, dysphoria, nausea, and generalized convulsion.¹¹⁴ The likelihood of an individual developing these symptoms is affected by a number of factors, including the depth and time of the exposure, exercise rate, immersion, and the partial pressure of inspired carbon dioxide. Symptoms may have a sudden onset and convulsions often occur with

little warning. If the patient is not post-ictal, symptoms typically disappear rapidly after discontinuation of oxygen breathing."

C. OPHTHALMIC MANIFESTATIONS

Ocular symptoms are a well recognized manifestation of CNS oxygen toxicity.^{9-12,17,71,98} The most commonly described ocular symptoms of CNS oxygen toxicity are eyelid twitching, blurred vision, and visual field constriction. Visual hallucinations" and transient unilateral loss of vision" have also been reported. The patient who experienced the unilateral visual loss had a previous history of retrobulbar optic neuritis in the index eye. Loss of the peripheral visual held may be severe, but is reversible upon termination of the hyperoxic exposure. In one study, 18 subjects breathed oxygen at a partial pressure of 3.0 ATA for up to 3.5 hours. Peripheral visual held loss began at 2.5 to 3.0 hours of exposure and progressed to an average loss of 50% of the total field.⁹⁸ Central visual acuity was not affected and recovery of peripheral vision was complete 3045 minutes after the exposure was terminated.

Another study examined changes in visual reaction time as a predictor of imminent overt CNS oxygen toxicity, but no predictive value was discovered."

D. TREATMENT

When CNS oxygen toxicity is encountered, oxygen breathing should be discontinued immediately. In most cases, symptoms resolve within several minutes, although some episodes progress to generalized convulsions despite a reduction in the oxygen partial pressure. CNS oxygen toxicity typically is without residua, unless secondary trauma or other complications ensue from a convulsion.

X. Other Ophthalmic Effects of Hyperbaric Oxygen

A myopic change in refraction following repeated hyperbaric oxygen treatments may cause a reduction in visual acuity.^{4,5,74,98} The rate of myopic change in patients receiving daily HBO treatments has been reported to be approximately 0.25 diopters per week and was progressive throughout the course of HBO therapy.⁴ This change is attributed to an increase in the refracting power of the lens.' Reversal of the myopia after cessation of therapy usually occurs within 3-6 weeks, but may take as long as 6-12 months.⁹⁸

The development of cataracts has been reported in patients undergoing a prolonged course of daily HBO therapy at 2.0-2.5 ATA.^{74,98} Seven of fifteen patients with clear nuclei at the start of therapy developed cataracts during their treatment course. These lens opacities were not completely reversible after HBO therapy was discontinued.⁷⁴

Hyperbaric oxygen has been shown to be a powerful retinal vasoconstrictor.^{50,72} The reduced blood flow caused by the vasoconstriction is offset by the greatly increased oxygen-carrying capacity of the blood in hyperoxic environments, with the retinal venous oxygen saturation increasing by as much as 23% while oxygen is breathed at 1 ATA.⁷² This increase in oxygen-carrying capacity may not be protective in all cases, however. The presence of a cotton-wool spot associated with a visual held defect presenting two weeks after hyperbaric oxygen breathing in a healthy 44-year-old man has been reported." No symptoms were noted during oxygen-breathing and subsequent fluorescein angiography revealed no vascular abnormalities and no areas of capillary non-perfusion.

Oxygen exposures at 3 ATA have been shown to cause selective damage to the rod cells in the retina." A decrease in rod sensitivity associated with breathing hyperbaric oxygen was reported by one author,"" but this effect was not found to result in significant changes in dark adaptation in a second study.""

XI. Hyperbaric Oxygen Therapy for Ocular Disorders

The success of hyperbaric oxygen therapy in treating the ischemia produced by DCS and AGE has led to its use in other clinical disorders. Among these are several ocular diseases.

A. CYSTOID MACULAR EDEMA

Hyperbaric oxygen has been proposed as a therapeutic modality for chronic cystoid macular edema (CME).⁷⁵ Ogura et al reported two patients treated with HBO for CME which followed a branch retinal vein occlusion." Visual acuities were 20/70 in both eyes following the development of CME and were not improved by argon laser photocoagulation. Oxygen treatments were administered at 2 ATA for one hour and were repeated twice a day for 14 days in both cases, with one patient receiving once-a-day treatments for a third week. Acuities after HBO treatment were 20/30 and 20/20 two months and one month after treatment, respectively. Benner and

Xiaoping" reported success in treating three patients with chronic aphakic CME with oxygen delivered at 1 ATA into a goggle chamber. Treatments were for six hours per day, six days a week for three weeks. Visual acuities in both patients for whom 10-month follow-up was obtained improved from 20/80 to 20/30. The mechanism by which HBO improves vision in this disorder is not well understood.**

B. RADIATION-INDUCED OPTIC NEUROPATHY

Guy and Schatz⁴⁸ reported the successful treatment of radiation-induced optic neuropathy with HBO. Two patients treated with HBO within 72 hours following the onset of visual loss had a return of visual function to baseline levels. Treatment of two other patients two and six weeks after the onset of symptoms was not effective. The authors recommend emergent HBO therapy for patients with radiation optic neuropathy if the symptoms have been present less than two weeks. A more recent report documents the complete reversal of visual field loss due to radiation-induced optic neuropathy with HBO therapy.'

C. CENTRAL RETINAL ARTERY OCCLUSION

Currently accepted therapy for central retinal artery occlusion (CRAO) includes supplemental oxygen.⁴⁶ It has been proposed that hyperbaric oxygen would allow the entire retinal demand for oxygen to be met by the choroidal circulation.²⁶ HBO would seem to be a logical treatment for cases of CRAO if supplemental oxygen at 1 ATA is not effective and the patient has not already suffered irreversible retinal damage.

The rationale for therapeutic success in treating CRAO with HBO depends therefore on an intact choroidal circulation. The brief temporal window in which this therapy must be employed also presents a problem in the use of HBO for treatment of CRAO. One study in which HBO therapy was used in 69 patients with retinal arterial occlusions 1-2 days after the onset of visual loss showed no clear benefit from this treatment.⁶⁷ Anderson et al reported three patients with central retinal artery occlusion treated with HBO. No benefit was noted in the two patients who were treated 40 hours and six days after the onset of symptoms. A third patient treated within hours after the onset of symptoms recovered from finger counting to 20/20 vision.³

An additional concern is the oxygen-induced retinal vasoconstriction discussed previously. Al-

though carbon dioxide has a vasodilating effect on the cerebral vasculature, oxygen and carbon dioxide mixtures often recommended for therapy of CRAO⁴⁶ should not be used in hyperbaric settings because of the potentiation of CNS oxygen toxicity caused by the latter gas.

D. RHINO-ORBITAL-CEREBRAL MUCORMYCOSIS

Fungal organisms of the family Mucoraceae can cause a devastating disease process in immunocompromised individuals. The rhino-orbital-cerebral variant of this disorder is initiated when an airborne spore colonizes the nasal mucosa. In individuals with normal immune systems, the spores are usually contained by a phagocytic response. In immunocompromised individuals, however, germination may ensue and hyphae then develop.¹¹⁵ As the infection progresses, the hyphae invade blood vessel walls and cause tissue hypoxia and necrosis. The mainstays of therapy are intravenous amphotericin B and surgical debridement, but permanent neurological deficits or death may ensue despite aggressive therapy with both modalities.

Hyperbaric oxygen markedly elevates the arterial partial pressure of oxygen. At a pressure of 2 ATA, breathing 100% oxygen generally results in an arterial oxygen pressure of 1000-1200 mm Hg. At 3 ATA, this increases to 1500-1800 mm Hg.⁶⁹ Elevated partial pressures of oxygen have been shown to be fungistatic.⁸² In addition, the oxygen may help to reverse the tissue hypoxia and necrosis caused by the propensity of the fungal hyphae to invade blood vessels. The clinical use of HBO in rhino-orbital-cerebral mucormycosis was first reported by Price and Stevens in a patient who subsequently recovered despite refusing surgical therapy.⁷⁸ Other authors have reported an apparent benefit from the use of HBO in conjunction with amphotericin B and surgery.^{21,37,42,43} In their review of rhino-orbital-cerebral mucormycosis, Yohai et al identified 28 patients with bilateral involvement who would be expected to have a very poor prognosis. Of the 18 patients who received amphotericin B and/or surgical therapy without HBO, only four survived. Six patients were also treated with HBO; of this group, five survived." Despite the small size of this sample, the authors found a statistically significant benefit from HBO therapy.

E. UHMS RECOMMENDED INDICATIONS

The Undersea and Hyperbaric Medical Soci-

ety (UHMS) in Kensington, Maryland, is an international scientific organization founded to foster the exchange of data on the physiology and medicine of diving and hyperbaric exposures. This organization has a standing Committee on Hyperbaric Oxygen Therapy which was established in 1976 to review the scientific and clinical data on the evolving applications of hyperbaric oxygen and to provide recommendations on which diseases and conditions are currently recognized indications for HBO therapy. At approximately three-year intervals, this committee publishes a report with an updated list of the recommended indications for HBO therapy for use as guidelines by third party payers and practitioners of hyperbaric medicine. The most recent publication by this committee was in 1992 and included necrotizing soft tissue infections as an indication for HBO.⁹⁹ Although the discussion of this indication focuses primarily on bacterial infections, it also states that HBO should be helpful in all necrotizing soft tissue infections, which would include rhino-orbital-cerebral mucormycosis. CME, radiation-induced optic neuropathy, and CRAO were not listed as recommended indications.

XII. Diving After Eye Surgery

Individuals who have undergone ophthalmic surgical procedures should allow an appropriate period of time for wound healing before resuming diving. Diving entails a number of factors which increase the risk of post-operative complications:

1) the water in which diving is performed often harbors pathogens which may cause infections when they contaminate non-epithelialized wound surfaces of the cornea, sclera, conjunctiva, or lid tissues;

2) these pathogens may enter the eye through non-healed corneal or scleral wounds and result in vision-threatening endophthalmitis;

3) gas in the anterior chamber or vitreous cavity may be affected by changes in pressure and result in vision-threatening intraocular barotrauma; and

4) face mask barotrauma may result in subconjunctival hemorrhage, lid ecchymosis and edema, and could theoretically cause the rupture of incompletely healed corneal or scleral wounds.

The risk of infection due to contact of the eye with water is much greater with diving in potentially contaminated ocean, river, or lake water than with showering or bathing in chlorinated

city water. If the hyperbaric exposure being considered is a chamber dive in which no face mask is worn and immersion is not anticipated, only item (3) above remains a consideration.

No controlled studies specifically addressing the requisite length of convalescence before a return to diving were found in the literature. The recommendations below are based on the application of wound healing observations in other studies and on clinical experience.

A. CORNEAL SURGERY

The possibility of barotrauma-induced rupture of a corneal wound is a theoretical possibility after any incisional corneal surgery and suggests that a convalescent period should be allowed for the corneal wound to heal before returning to diving. Studies on the healing rate of corneal wounds have been done in the case of full thickness incisions. "Very little healing is noted in the first week, followed by a rapid rise to about 30% of normal strength at one month. Wound strength then gradually increases to approximately 50% of normal by 3-6 months."^{19,44} Surgical procedures such as penetrating keratoplasty in which full-thickness incisions are made in the cornea should be followed by a six-month convalescent period before a return to diving. Patients who have undergone radial and astigmatic keratotomy, which do not entail full-thickness corneal incisions or prolonged topical steroid therapy, may be allowed to dive after three months. Since eyes in animal models which have had microperforations at surgery have been shown to rupture at significantly lower pressures than those without such occurrences, "consideration should be given to extending the convalescent period prior to diving in eyes with micro- or macroperforations at the time of RK. Photorefractive keratectomy, in which there are no such incisions, permits a return to diving after re-epithelialization of the cornea is complete and acute post-operative symptoms subside.

B. CATARACT SURGERY

The limbal wounds made in extracapsular cataract surgery heal more rapidly than clear corneal wounds because of the increased limbal blood supply. It is common surgical practice to remove sutures from these incisions at two months, indicating that a three-month wait should be adequate to allow for wound healing before diving is resumed. Scleral tunnel incisions now used in single-stitch or sutureless phacemulsification cataract procedures are designed

to be self-sealing as a result of the pressure of the aqueous humor on the corneal valve. The possibility of pathogens entering the eye through the healing scleral tunnel must also be considered, however. A one-month period of convalescence is recommended for patients with scleral tunnel incisions, and a two-month period is recommended after procedures employing corneal valve incisions made in clear cornea.

C. VITREORETINAL SURGERY

Vitreoretinal surgery poses a different set of considerations. The small scleral incisions made in pars plana vitrectomies and for drainage of subretinal fluid in retinal detachment repair would be expected to be well healed after two months. The presence of any intraocular gas following a vitreoretinal procedure is an absolute contraindication for diving (or flying) and the patient should be warned of this fact after the procedure.

D. GLAUCOMA FILTERING SURGERY

Patients who have undergone glaucoma filtering surgery are at risk for two complications should they elect to dive after their surgery. A face mask squeeze could result in subconjunctival hemorrhage and chemosis that may compromise the function of their filter. The risk of this occurrence is small, however, because of the low incidence of significant face mask barotrauma. No reports were found which documented the loss of a functioning filter as a result of this complication.

The well-known risk of late endophthalmitis in patients with filtering blebs raises the question of pathogens gaining access to the anterior chamber through the conjunctiva. This is more of a problem in the setting of bacterial conjunctivitis, and has not been reported as a complication of diving. The small magnitude of the risk to patients from these two complications makes the presence of a functioning filter a relative rather than an absolute contraindication to diving. A minimum of two month's convalescence is recommended after this procedure. Patients who elect to continue diving with a filter should be advised of the risk of these two complications and the need to avoid face mask barotrauma.

E. CORNEOSCLERAL SUTURE REMOVAL

Removal of corneoscleral sutures after cataract surgery or glaucoma filtering surgery has the potential to create microscopic tracts into the corneal stroma and possibly the anterior cham-

ber. A one-week wait before diving is recommended after removal of corneoscleral sutures.

F. OTHER SURGERY

Most other types of ocular surgery do not predispose to a significant risk of intraocular barotrauma, corneoscleral wound rupture, or intraocular infection. These procedures require only a long enough period to allow reepithelialization of the wound and for acute post-operative symptoms to subside. A period of two weeks should suffice in these cases. A summary of various ophthalmic surgical procedures and their recommended convalescent periods prior to diving is provided in Table 3.

XIII. Ophthalmic Considerations in Fitness-to-Dive Evaluations

Guidelines have been published on medical standards for divers which include ocular considerations.^{25,30,51,66} These standards are published by such diverse groups as the National Institute of Occupational Safety and Health, the US Navy, the British Commercial Diving Industry and various diving medicine specialists, and vary somewhat in their recommendations. It is important to consider precisely what question is being answered before reviewing the ophthalmic standards for hyperbaric exposures.

Fitness-to-dive evaluations are performed in two settings. The first is an evaluation done for a patient who is a recreational diver and asks his or her personal physician "Is it safe for me to dive?" This calls for a response based solely on medical safety considerations for the patient.

The second type of fitness-to-dive evaluation is one done in an occupational setting where a patient who is or hopes to be a military or commercial diver is evaluated by a physician who works for the employer. In this case, the interests of both the employer and the patient must be considered and the physical standards which are established may be quite different depending on the mission to be accomplished by the diver in each setting.

Additional questions must be considered in occupational settings. Is it economically feasible to expend significant medical specialty resources to determine fitness to dive for candidates who have borderline conditions when there is a very large pool of candidates to draw from who do not require such evaluation? What is the potential medicolegal and workman's compensation liability to the employer who allows individuals with borderline conditions to dive? What is the indi-

vidual's value to the employer based on the training and experience he or she has accumulated? These questions may be exceedingly complex and must be answered differently in each occupational setting and for each individual circumstance.

The fitness-to-dive recommendations found in the following paragraphs will focus only on medical safety considerations for the patient and attempt to address three issues:

- 1) Does the condition impair the individual in such a way as to endanger him or her in the hazardous hyperbaric environment (e.g., inadequate visual acuity);
- 2) Is the condition one which may be made worse by hyperbaric exposures (e.g., neurological residua from DCS);
- 3) Would hyperbaric exposures possibly result in complications from a pre-existing condition (e.g., intraocular barotrauma from diving with intraocular gas).

A. VISUAL ACUITY

What level of visual acuity is required to dive safely? Specific acuity limits recommended or required by different sources vary considerably.^{30,51,63,66,103} In fact, diving is a relatively undemanding activity from a visual standpoint when compared to other activities, such as driving. Anyone who is able to see well enough to operate an automobile traveling at 65 mph on a freeway should be able to dive safely from a visual acuity standpoint. In many diving environments, visibility may be several feet or less, even for an individual with excellent vision, so every diver should be capable of functioning in conditions of markedly reduced visibility. The ability to see well enough to possess a driver's license is a convenient and reasonable standard for visual acuity in diving. If a person fails to meet this criterion, the decision on fitness to dive must be based on a careful assessment of the patient's ability to function with his or her level of vision and the particulars of diving in which he or she wishes to participate.

B. COLOR VISION

Color vision is not required for safe functioning in the underwater environment.^{25,30,63} As described in Section III, colors may be altered or absent at great depths or in conditions of reduced visibility. The requirements concerning color vision in occupational diving standards stem from the practice of color-coding SCUBA bottles and supply lines containing different gases or from other occupational considerations.

TABLE 3
Recommended Minimum Convalescent Periods Prior to Diving after Ophthalmic Surgery

Procedure	Recommended Convalescent Period
<i>Anterior segment surgery</i>	
Penetrating keratoplasty	6 months
Corneal laceration repair	6 months
<i>Cataract surgery</i>	
Non-corneal valve incision	3 months
Corneal valve incisions	
Clear corneal	2 months
Scleral tunnel	1 month
Radial keratotomy	3 months
Astigmatic keratotomy	3 months
Glaucoma filtering surgery	2 months
	(Relative contraindication)
Photorefractive keratectomy	2 weeks
Pterygium excision	2 weeks
Conjunctival surgery	2 weeks
Corneal suture removal	1 week
Argon laser trabeculoplasty or iridectomy	No wait necessary
Yag laser capsulotomy	No wait necessary
<i>Vitreoretinal surgery</i>	
Vitrectomy	2 months (Diving contraindicated until intraocular gas resorbed)
Retinal detachment repair	2 months
Pneumatic retinopexy	2 months (Diving contraindicated until intraocular gas resorbed)
Retinal cryopexy or laser photocoagulation for breaks	2 weeks
<i>Oculoplastic surgery</i>	
Sutured wound	2 weeks
Skin graft or granulating wound	Until epithelialization is complete
Enucleation	2 weeks (Diving contraindicated with hollow orbital implants)
<i>Strabismus surgery</i>	2 weeks

This is not a concern to the vast majority of recreational divers who confine themselves to air diving. Poor color vision may call for increased care in the case of the minority of recreational divers who dive using cylinders of specially prepared mixtures of nitrogen and oxygen (nitrox). The increased percentage of oxygen in these mixtures may result in CNS oxygen toxicity if

used at depths where the partial pressure of oxygen exceeds 1.2 ATA. Careful labelling of nitrox cylinders in addition to color coding should suffice to avoid confusion between the two gas mixtures.

C. CORNEAL AND CATARACT SURGERY

Questions about diving after radial keratotomy (RK) are often encountered. Individuals whose myopia has been corrected with this procedure are prohibited from entering diving programs in the Navy.³⁴ Applicants who have had this procedure may not even be allowed to serve in less visually demanding military positions.³⁴ Two recent reviews of RK in the military have recommended that the procedure continue to be disqualifying for Navy divers³⁵ and for Army aviators.³⁶ Edmonds et al²⁹ recommend that people who have had RK not be allowed to dive unless they use face masks designed to equalize the pressure within the mask to that of the ambient pressure. Davis³⁵ states that until further data is available, a person who has had RK should be disqualified from diving.

The potential complications of RK are well documented and include halos, glare, diurnal fluctuations in visual acuity, progressive hyperopia, irregular astigmatism, decrease in best corrected visual acuity, recurrent corneal erosions, and increased susceptibility to traumatic corneal rupture.^{35,45,80,109,110} The additional question of possible barotrauma-induced rupture of RK incisions in the hyperbaric environment is often raised when evaluating these individuals for fitness to dive.

Alcaraz found that the pressure required to rupture at least one corneal incision in post-RK human cadaver eyes is approximately 215 mm Hg.¹ Additional information is available from animal models. Campos et al studied 20 enucleated pig eyes that had undergone either RK or PRK.³⁷ Intraocular pressure was then raised using lateral compression until the eye ruptured or until a maximum measurable pressure of 280 mm Hg was reached. Nine of the 10 control eyes ruptured at the sclera, and the other ruptured at the optic nerve. All control eyes ruptured at pressures above 280 mm Hg. Similar results were obtained with the PRK eyes, with all 10 eyes rupturing at scleral sites at pressures above 280 mm Hg. In contrast, all 10 of the RK eyes ruptured at corneal incision sites at an average pressure of 240 mm Hg. Other studies have also shown an increased susceptibility to pressure-induced rupture of the globe after RK in animal models.^{64,83} It is important to note that animal models designed

to study corneal weakening after RK often involve surgery on postmortem eyes and do not allow for postoperative wound healing.

Although the absolute pressure may increase well beyond the pressures described above during diving, there is generally not a significant pressure differential across the cornea except in the case of a face mask squeeze. As mentioned previously, this is an uncommon occurrence in diving since the diver need only be able to exhale through a single nostril during descent to prevent its development. The author has seen only one clinically significant case of face mask barotrauma in many years of association with Navy and recreational diving activities.

Despite the theoretical potential for corneal rupture to occur in divers who have had RK, such occurrences have not been reported.³⁸ Most of the reported corneal ruptures following RK have been the result of direct blunt trauma to the eye.^{39,45,65,80} Also worthy of note are the reports of blunt trauma severe enough to cause hyphema and facial fractures in which radial keratotomy scars remained intact.^{33,91}

Kluger recommends that RK not be considered a contraindication to diving in his review on diving after corneal surgery.³⁹ The author has examined three US Navy divers and one Coast Guard diver who underwent bilateral RK subsequent to completing initial diver training, presumably being unaware of the restrictions on refractive surgery for divers. These individuals had continued to dive for varying lengths of time after their procedures before being referred for ophthalmic evaluation for fitness to dive. They had all returned to diving shortly after having had RK performed and had, by the time of their evaluation, been diving for periods of four to ten years without suffering corneal wound dehiscence or other adverse effects. All were allowed to continue diving and have had, to the author's knowledge, no problems related to their eye surgery.

There were also no reports of any corneal wound ruptures occurring as a result of diving in patients who had undergone penetrating keratoplasty. Although the potential for rupture is greater than that in eyes which have only undergone the partial thickness incisions of radial keratotomy, this risk also remains theoretical and at present should not be considered a contraindication to diving after the patient has been appropriately informed and the recommended six-month convalescent period has passed.

Photorefractive keratectomy (PRK) is a new refractive surgical procedure which is currently

in phase III of FDA testing. Unlike radial keratotomy, it entails no corneal incisions which would decrease the ability of the cornea to withstand blunt trauma. Published series of PRK cases have shown that the incidence of visually significant post-operative complications experienced with this procedure is very low.^{76,84,85,93} As noted above, this procedure was not found to increase the susceptibility of the eye to rupture when subjected to elevated pressures. "Individuals who have had this procedure may be allowed to dive two weeks after their surgery, assuming that they have had an uneventful postoperative course with resolution of pain and photophobia.

No reports were found of barotrauma-induced wound rupture or other complications occurring as a result of diving after cataract surgery. Diving after this type of surgery should also not pose a problem after the recommended convalescent period.

D. ENUCLEATION

After the convalescent periods recommended in the previous section, diving should be possible after almost any type of eye surgery. One exception is an individual who has undergone enucleation and who has a hollow implant. There are reports of pressure-induced collapses of hollow silicone orbital implants at depths as shallow as 10 feet. "A hollow glass implant was also tested and did not implode at a maximum test depth of 115 feet, but diving with hollow glass implants could not be recommended on the basis of this one test. Individuals with hollow orbital implants should not dive.

E. GLAUCOMA

The question of whether or not patients who have glaucoma should dive is an intriguing one. Ophthalmologists treat glaucoma by reducing the intraocular pressure. A doctor who has intervened therapeutically to reduce the pressure in the eye of a glaucoma patient from 25 to 15 mm Hg may be concerned at the prospect of the pressure in this eye being increased to over 2000 mm Hg when he or she descends to a depth of 60 FSW. Saturation divers working at a depth of 800 feet have intraocular pressures of over 19,000 mm Hg. They remain at these depths for durations exceeding 30 days without suffering any symptoms of glaucomatous optic neuropathy.

How is this possible! Clearly, the issue is not the absolute pressure to which the eye is ex-

posed, but rather the magnitude of the difference between the intraocular and extraocular pressures.⁷⁹ The picture is further complicated by current thoughts about the multifactorial etiology of glaucomatous optic neuropathy^{104,105} and the lack of investigational data about how these various factors are altered by exposure to an elevated absolute pressure. The only glaucoma patients who should be definitely excluded from diving are those with visual loss severe enough to impair their ability to function in the underwater environment. Functioning filters are a relative contraindication to diving, as noted previously. Glaucoma patients on medical therapy to control their pressures should be evaluated for the presence of side effects which may present problems during or after a dive. These are discussed in the following section.

F. VITREORETINAL DISORDERS

Retinal detachment surgery or treated retinal breaks should not be a problem for diving once the recommended convalescent period has passed. "Degenerative and metabolic ocular disorders have not been reported to be exacerbated by hyperbaric exposures. The limiting factor for such patients will be reductions in visual acuity or the limitations imposed by the systemic disorders themselves.

G. VISUAL RESIDUA FROM DECOMPRESSION SICKNESS

Many diving medical officers feel that neurological symptoms of decompression sickness which do not resolve after therapy may predispose to further episodes of DCS, although this has not been addressed in a controlled study. These residual deficits are felt to be contraindications to diving by some authors,²⁴ while others recommend that shallow diving be allowed if the residual deficits are stable over a period of months and not disabling. "The author recommends that any visually significant deficit from a previous episode of DCS be considered a contraindication to any further recreational or occupational compressed gas diving.

H. MISCELLANEOUS

Patients with breaks in the corneal epithelium should not dive until these breaks are completely re-epithelialized. In fact, most patients will probably not feel much like diving until these breaks are healed. Individuals in the acute phase of any ocular disorder which produces significant pain, decreased visual acuity, photophobia, diplopia,

TABLE 4

Ophthalmic Contraindications to Diving

-
1. Intraocular gas
 2. Presence of a hollow orbital implant
 3. Any acute infectious or inflammatory ocular disorder which produces significant pain, photophobia, diplopia, or decrease in vision
 4. Recent ophthalmic surgery prior to completion of the recommended convalescent period
 5. Inadequate vision to function safely in the underwater environment
 6. Visually significant deficits from previous episodes of decompression sickness or arterial gas embolism
 7. Functioning glaucoma filter (relative contraindication)
-

or other disabling symptoms should refrain from diving until the problem has been treated and the acute symptoms have resolved.

Table 4 provides a summary of ophthalmic contraindications to diving. Once again, most of the restrictions to diving noted above do not apply to hyperbaric oxygen therapy. Hyperbaric exposures which occur in a dry chamber do not entail immersion of the eye or the possibility of face mask barotrauma. Decompression sickness is a consideration only for chamber attendants not breathing 100% oxygen. Many critically ill patients are routinely treated in dry chambers with HBO. Only the presence of intraocular gas or hollow orbital implants remain as possible ocular contraindications to diving in these patients.

XIV. Ocular Medications and Diving

The use of ocular medications may present special problems in the underwater environment. Probably the most common agents encountered are anti-glaucoma medications, antibiotics, and antiinflammatory agents.

A. TOPICAL BETA-BLOCKERS

Timolol and other beta-adrenergic antagonists are commonly used antiglaucoma medications with few side effects in otherwise healthy individuals.⁷ Potential adverse effects of the use of topical beta-adrenergic antagonists include decreased heart rate, exacerbation of pre-existing congestive heart failure (CHF), bronchospasm in individuals with asthma or chronic obstructive pulmonary disease (COPD), and fatigue. These agents do not typically cause CHF or bronchospasm in patients without pre-existing disease, and patients who suffer from CHF,

asthma, or COPD should neither be allowed to dive nor given beta-blockers.

Timolol has been reported to reduce the heart rate in glaucoma patients from 79 to 71 beats per minute without having any appreciable effect on blood pressure.¹⁰⁸ In another study comparing the cardiovascular effects of timolol and apraclonidine on healthy female volunteers, timolol was found to reduce both the resting heart rate and exercise-induced tachycardia.¹⁸ Since a small percentage of divers may be at risk of loss of consciousness underwater from vagotonic bradyarrhythmias when diving in cold water,¹⁰¹ timolol may be considered to increase this risk. Supraventricular tachyarrhythmias may also place the diver at hazard, however,⁸ and timolol may have a protective effect against this occurrence. It should be noted that increased vagal tone and a resting bradycardia are common in well-conditioned individuals,⁸ and that this bradycardia is not considered a contraindication to diving. Patients who wish to dive while on timolol should wait several weeks after therapy is initiated and have their heart rate checked by a physician. If the heart rate is normal, diving should be permitted. If a significant bradycardia exists, the advice of a diving medicine consultant should be obtained.

B. Pilocarpine

Pilocarpine causes miosis and stimulation of the ciliary muscle.⁷⁰ This may result in frontal headache as well as reduced peripheral and scotopic vision. Fluctuations in visual acuity may be very bothersome to younger patients on pilocarpine. Although pilocarpine is a parasympathetic agonist and theoretically may cause bradyarrhythmias, this is generally not clinically significant.¹⁰⁹ Patients recently started on pilocarpine should be examined before being allowed to return to diving to ensure that they are not having headaches which may be confused with DCS after a dive. Fluctuating visual acuity may be treated by switching to a sustained-released delivery system, although the effects, if any, of the hyperbaric environment on the sustained-release delivery system are not known. Mild reductions in peripheral vision and night vision should not prevent an individual from diving safely.

C. DIPIVEFRIN

Dipivefrin produces the most troublesome ocular surface symptoms of the three commonly used topical anti-glaucoma medications, but is

relatively free of adverse systemic effects. Therapy with this agent should not impact on fitness to dive.

D. CARBONIC ANHYDRASE INHIBITORS

Acetazolamide and methazolamide are carbonic anhydrase inhibitors used to lower intraocular pressure in glaucoma patients when topical medications alone are insufficient or are not tolerated. Side effects from these agents include renal calculi, paresthesias, electrolyte and acid-base disturbances, depression, skin eruptions, loss of appetite, and blood dyscrasias.⁸⁶ The most common symptom encountered with carbonic anhydrase inhibitors which would be problematic for diving is the peripheral paresthesias which could easily be mistaken for manifestations of neurological DCS. Divers started on these medications should be checked four to six weeks after the initiation of therapy. Should significant paresthesias be present, the medication should be discontinued and other treatment modalities, such as argon laser trabeculoplasty, undertaken. Patients with clinically significant depression or mood change resulting from carbonic anhydrase inhibitor therapy should be counseled not to dive unless the medication is discontinued. A blood count and serum electrolytes should be checked before allowing a patient recently started on carbonic anhydrase inhibitor therapy to dive.

E. TOPICAL STEROIDS

Longterm therapy with topical steroids may cause increased intraocular pressure and cataracts. Of more concern in the evaluation for diving is the disorder for which the steroids are prescribed. If the patient is receiving steroids after intraocular or corneal surgery, the convalescent periods recommended previously should be adhered to. If the patient is suffering from an ocular inflammatory disorder, the acutely symptomatic phase of the disease should be allowed to pass before diving is resumed.

F. TOPICAL ANTIBIOTICS AND ANTIVIRAL AGENTS

Topical antibiotics and antiviral agents have no systemic effects which should interfere with diving. Diving should be curtailed until the acute symptoms from the infectious process have resolved.

XV. Miscellaneous Ocular Problems

One diving medicine textbook⁷⁷ mentions in-

stances of divers becoming aware of bubbles forming in the medial canthus of the eye while performing the Valsalva maneuver to equalize their ears. This phenomenon may occur if the valve of Hasner allows air to enter the nasolacrimal duct during the Valsalva maneuver. The air then travels up the duct and exits at the punctal openings.

References

1. Alcaraz LG, Banez MA, Haight DH, et al: Comparative study of wound integrity after excimer laser photoablation and radial keratotomy (abstract). *Invest Ophthalmol Vis sci* 33 (Suppl):999, 1992
2. Andenmatten R, Piguët B, Klainiguti G: Orbital hemorrhage induced by barotrauma (letter). *Am J Ophthalmol* 118:536-537, 1994
3. Anderson B, Saltzman H, Heyman A: The effects of hyperbaric oxygenation on retinal arterial occlusion. *Arch Ophthalmol* 73:3 15-3 19, 1965
4. Anderson B, Farmer JC: Hyperoxic myopia. *Trans Am Ophthalmol Soc* LXXVI: 116-1 24, 1978
5. Anderson B, Shelton DL: Axial length in hyperoxic myopia, in Bove AA, Bachrach AJ, Greenbaum LJ (eds): *Ninth International Symposium on Underwater and Hyperbaric Physiology*. Bethesda, Undersea and Hyperbaric Medical Society, 1987, pp 607-611
6. Benner JD, Xiaoping M: Locally administered hyperoxic therapy for aphakic cystoid macular edema (letter). *Am J Ophthalmol* 113:104-105, 1992
7. Borruat FX, Schatz NJ, Glaser JS, et al: Visual recovery from radiation-induced optic neuropathy. *J Clin Neuroophthalmol* 13:98-101, 1993
8. Bove AA: Cardiovascular disorders and diving, in Bove AA, Davis JC (eds): *Diving Medicine*. Philadelphia, WB Saunders, 1990, ed 2, pp 245-246
9. Butler FK, Thalmann ED: Central nervous system oxygen toxicity in closed circuit SCUBA divers, in Bachrach AJ, Matzen MM, (eds): *Underwater Physiology VIII. Proceedings of the Eighth Symposium on Underwater Physiology*. Bethesda, Undersea Medical Society, 1984, pp 15-30
10. Butler FK: *Closed-circuit Oxygen Diving*. US Navy Experimental Diving Unit Report 7-85, 1985
11. Butler FK, Thalmann ED: Central nervous system oxygen toxicity in closed circuit SCUBA divers II. *Undersea Biomed Res* 13:193-223, 1986
12. Butler FK: Central *Nervous System Oxygen Toxicity in Closed Circuit SCUBA Divers III*. US Navy Experimental Diving Unit Report 5-86, 1986
13. Butler FK, Pinto C: Progressive ulnar palsy as a late complication of decompression sickness. *Ann Emerg Med* 15:738-741, 1986
14. Butler FK: Decompression sickness, in Gold DH, Weingeist TA, (eds): *The eye in Systemic Disease*. Philadelphia, JB Lippincott, 1990, pp 469-471
15. Butler FK: Decompression sickness presenting as optic neuropathy. *Aviat Space Environ Med* 62:346-350, 1991
16. Campos M, Lee M, McDonnell P: Ocular integrity after refractive surgery: effects of photorefractive keratectomy, phototherapeutic keratectomy and radial keratotomy. *Ophthalmic Surg* 23:598-602, 1992
17. Clark JM: Oxygen toxicity, in Bennett PB, Elliott DH (eds): *The Physiology and Medicine of Diving*. London, WB Saunders, 1993, ed 4, pp 121-169
18. Coleman AL, Robin AL, Pollack IP, et al: Cardiovascular and intraocular pressure effects and plasma concentrations of apraclonidine. *Arch Ophthalmol* 108: 1264-1267, 1990

19. Condon PI, Hill DW: The testing of experimental corneal wounds stitched with modern corneal scleral sutures: experimental corneal wound healing. *Ophthalmol Res* 5:137-150, 1973
20. Cotter J: Soft contact lens testing on fresh water SCUBA divers. *Contact Lens* 7:323-326, 1981
21. Couch L, Theilen F, Mader JT: Rhinocerebral mucormycosis with cerebral extension successfully treated with adjunctive hyperbaric oxygen therapy. *Arch Otolaryngol Head Neck Surg* 114:791-794, 1988
22. Curley MD, Butler FK: Visual reaction time preceding CNS oxygen toxicity. *Undersea Biomed Res* 14:301-310, 1987
23. Davis JC, Sheffield P, Shuknecht L, et al: Altitude decompression sickness: hyperbaric therapy results in 145 cases. *Aviat Space Environ Med* 48:722-730, 1977
24. Davis JC: Treatment of decompression sickness and gas embolism, in Bove AA, Davis JC (eds): *Diving Medicine*. Philadelphia, WB Saunders, 1990, ed 2, pp 258
25. Davis JC: Medical evaluation for diving, in Bove AA, Davis JC (eds): *Diving Medicine*. Philadelphia, WB Saunders, 1990, ed 2, pp 296
26. Dollery CT, Bulpitt CJ, Kohner EM: Oxygen supply to the retina from the retinal and choroidal circulations at normal and increased arterial oxygen tensions. *Invest Ophthalmol* 8:588-594, 1969
27. Ehmonds C, Lowry C, Pennefather J: *Diving and Subaquatic Medicine*. Oxford, Butterworth-Heinemann, 1992, ed 3, pp 21
28. *Ibid*, p 196
29. *Ibid*, pp 408-409
30. *Ibid*, p 469
31. *Ibid*, pp 481-482
32. Elizondo DR: Implications of radial keratotomy on physical disqualification for diving duty in the US Navy. *Undersea Medical Officer Thesis*, Naval Undersea Medical Institute, 1992
33. Elliott DH, Moon RE: Manifestations of the decompression disorders, in Bennett PB, Elliott DH (eds): *The Physiology and Medicine of Diving*. London, WB Saunders, 1993, ed 4, pp 481-505
34. Elsas EJ, Anderson B, Lefler WH: Hyperbaric oxygen and dark adaptation in man. *Aerospace Medicine* 39:970-971, 1968
35. Enzenhauser RW, Cornell FM, Wolter A, Tucker S: Radial keratotomy in the soldier-aviator. *Military Medicine* 158:521-528, 1993
36. Fang MD, Chen HM: Bubble formation of aqueous humor and lens opacity during chamber flight. *Aviat Space Environ Med* 55:910-913, 1984
37. Ferguson BI, Mitchell TG, Moon R, et al: Adjunctive hyperbaric oxygen therapy for treatment of rhinocerebral mucormycosis. *Rev Infect Dis* 10:551-559, 1988
38. Flynn ET: Decompression sickness, in Camporesi EM, Barker A: *Hyperbaric Oxygen Therapy: A Critical Review*. Bethesda, Undersea and Hyperbaric Medical Society, 1991, pp 55-74
39. Forsot SL, Damiano RE: Trauma after radial keratotomy. *Ophthalmology* 95:833-835, 1988
40. Francis TJR, Smith D (eds): *Describing Decompression Illness*. Bethesda, Undersea and Hyperbaric Medical Society, 1987
41. Francis TJR, Gorman DF: Pathogenesis of the decompression disorders, in Bennett PB, Elliott DH (eds): *The Physiology and Medicine of Diving*. London, WB Saunders, 1993, ed 4, pp 454-480
42. Galetta SL, Walc AE, Goldberg HI, et al: Rhinocerebral mucormycosis: management and survival after carotid occlusion. *Ann Neurol* 28:103-107, 1990
43. Gamba JL, Woodruff WW, Djang MD, Yeates AE: Craniofacial mucormycosis: Assessment with CT. *Radiology* 160:207-212, 1986
44. Gasset AR, Dohlman CH: The tensile strength of corneal wounds. *Arch Ophthalmol* 79:595-602, 1968
45. Glasgow BJ, Brown HH, Aizuss DH, et al: Traumatic dehiscence seven years after radial keratotomy. *Am J Ophthalmol* 106:703-707, 1988
46. Goldbaum MH: Central or branch retinal artery occlusion, in Fraunfelder FT, Roy FH (eds): *Current Ocular Therapy*. Philadelphia, WB Saunders, 1990, ed 3, pp 663-664
47. Greer HD: Neurological consequences of diving, in Bove AA, Davis JC (eds): *Diving Medicine*. Philadelphia, WB Saunders, 1990, ed 2, pp 224-225
48. Guy J, Schatz NJ: Hyperbaric oxygen in the treatment of radiation-induced optic neuropathy. *Ophthalmology* 93:1083-1088, 1986
49. Hart BL, Dutka AJ, Flynn ET: Pain-only decompression sickness affecting the orbicularis oculi. *Undersea Biomed Res* 13:461-463, 1986
50. Herbststein K, Murchland JB: retinal vascular changes after treatment with hyperbaric oxygen. *Med Journal Aust* 140:728-729, 1984
51. Hickey DD: Outline of medical standards for divers. *Undersea Biomed Res* 11:407-431, 1984
52. Isenberg SJ, Diamant A: Scuba diving after enucleation (letter). *Am J Ophthalmol* 100:616-617, 1985
53. John ME, Schmitt TE: Traumatic hyphema after radial keratotomy. *Ann Ophthalmol* 15:930-932, 1983
54. Josephson JE, Caffery BE: contact lens considerations in surface and subsurface aqueous environments. *Optom Vis Sci* 68:2-11, 1991
55. Kent PR: *Oxygen Breathing Effect Upon Night Vision Thresholds*. US Naval Submarine Medical Center Report 469, 1966
56. Kinney JS: *Human Underwater Vision; Physiology and Physics*. Bethesda, Undersea and Hyperbaric Society, 1985, pp 41-49
57. *Ibid*, pp 109-124
58. Kizer KW: Delayed treatment of dysbarism: A retrospective review of 50 cases. *JAMA* 247:2555-2558, 1982
59. Kluger M: Fitness to dive; Implications of corneal surgery. *S Pacific Undersea Med Soc J* 24:62-66, 1994
60. Lam TH, Yau KP: Manifestations and treatment of 793 cases of decompression sickness in a compressed air tunneling project in Hong Kong. *Undersea Biomed Res* 15:377-388, 1988
61. Larson BC, Kramer FB, Eller AW, Bernadino VB: Quantitated trauma following radial keratotomy in rabbits. *Ophthalmology* 90:660-667, 1983
62. Liepmann M: Accommodative and convergence insufficiency after decompression sickness. *Arch Ophthalmol* 99:453, 1981
63. Linaweaver PG, Bove AA: Physical examination of divers, in Bove AA, Davis JC (eds): *Diving Medicine*. Philadelphia, WB Saunders, 1990, ed 2, pp 306-307
64. Luttrell JK, Jester JV, Smith RE: The effect of radial keratotomy on ocular integrity in an animal model. *Arch Ophthalmol* 100:319-320, 1982
65. McDermott ML, Wilkinson WS, Tukul DB, et al: Corneal rupture ten years after radial keratotomy (letter). *Am J Ophthalmol* 110:575-577, 1990
66. Mebane GY, McIver NKI: Fitness to Dive, in Bennett PB, Elliott DH (eds): *The Physiology and Medicine of Diving*. London, WB Saunders, 1993, ed 4, pp 59-60
67. Miyake Y, Horiguchi M, Matsuura S, et al: Hyperbaric oxygen therapy in 72 eyes with retinal arterial occlusion, in Bove AA, Bachrach AJ, Greenbaum LJ (eds): *Ninth International Symposium on Underwater and Hyperbaric Physiology*. Bethesda, Undersea and Hyperbaric Medical Society, 1987, pp 949-953
68. Miyake Y, Awaya S, Takahashi H, et al: Hyperbaric oxygen and acetazolamide improve visual acuity in patients with cystoid macular edema by different mecha-

- nisms (letter). *Arch Ophthalmol* 111:1605-1606, 1993
69. Moon RE, Camporesi EM, Shelton DL: Prediction of arterial PO₂ during hyperbaric treatment, in Bove AA, Bachrach AJ, Greenbaum LJ (eds): **Ninth International Symposium on Underwater and Hyperbaric Physiology**. Bethesda, Undersea and Hyperbaric Medical Society, 1987, pp 1127-1131
 70. Nardin GF, Zimmerman TJ, Zalta AH, Felts K: Ocular cholinergic agents. in Ritch R, Shields MB, Krupin T (eds): *The Glaucomas*. St Louis, CV Mosby, 1989, pp 515-518
 71. Nichols CW, Lambertson CJ, Clark J: Transient unilateral loss of vision associated with oxygen at high pressure. *Arch Ophthalmol* 81:548-552, 1969
 72. Nichols CW, Lambertson CJ: Effects of high oxygen pressures on the eye. *N Engl J Med* 281:25-30, 1969
 73. Ogura Y, Takahashi M, Ueno Y, Honda Y: Hyperbaric oxygen treatment for chronic cystoid macular edema after retinal branch vein occlusion (letter). *Am J Ophthalmol* 103:301-302, 1987
 74. Palmquist BM, Philipson B, Barr PO: Nuclear cataract and myopia during hyperbaric oxygen therapy. *Br J Ophthalmol* 68:113-117, 1984
 75. Pfoff DS, Thorn SR: Preliminary report on the effect of hyperbaric oxygen on cystoid macular edema. *J Cataract Refract Surg* 13:136, 1987
 76. Piebenga LW, Matta CS, Deitz MR, et al: Excimer photorefractive keratectomy for myopia. *Ophthalmology* 100: 1335-1345, 1993
 77. Polkinghorne PJ, Cross MR, Sehmi K, et al: Ocular fundus lesions in divers. *Lancet* 1381-1383, 1988
 78. Price JC, Stevens DL: Hyperbaric oxygen in the treatment of rhinocerebral mucormycosis. *Laryngoscope* 90: 737-747, 1980
 79. Quigley HA: Open-angle glaucoma. *N Engl J Med* 328:1097-1106, 1993
 80. Rashid ER, Waring GO: Complications of radial and transverse keratotomy. *Surv Ophthalmol* 34:73-106, 1989
 81. Rivera JC: Decompression sickness among divers — an analysis of 935 cases. *Military Med* 129:314-334, 1964
 82. Robb SM: Reactions of fungi to 10 atmospheres of pressure of oxygen. *J Gen Microbiol* 45:17-29, 1966
 83. Rylander H, Welch AJ, Fremming H: The effect of radial keratotomy on the rupture strength of pig eyes. *Ophthalmic Surg* 14:744-749, 1983
 84. Salz JJ, Maguen E, Nesburn AB, et al: A two-year experience with excimer laser photorefractive keratectomy for myopia. *Ophthalmology* 100:873-882, 1993
 85. Seiler T, Holsbach A, Derse M, et al: Complications of myopic photorefractive keratectomy with the excimer laser. *Ophthalmology* 101:153-160, 1994
 86. Shaffer RN: Open-angle glaucoma, in Fraunfelder FT, Roy FH (eds): *Current Ocular Therapy*. Philadelphia, WB Saunders, 1990, ed 3, pp 570-573
 87. Simon DR, Bradley ME: Corneal edema in divers wearing hard contact lenses. *Am J Ophthalmol* 85:462-464, 1978
 88. Simon DR, Bradley ME: Adverse effects of contact lens wear during decompression. *JAMA* 244: 1213-1214, 1980
 89. Socks JF, Molinari JF, Rowley JL: Rigid gas permeable contact lenses in hyperbaric environments. *Am J Opt Phys Optics* 65:942-945, 1988
 90. Somers LH: Diving physics, in Bove AA, Davis JC (eds): *Diving Medicine*. Philadelphia, WB Saunders, 1990, ed 2, pp 15-16
 91. Spivack L: Case report: Radial keratotomy incisions remain intact despite facial trauma from plane crash. *J Refract Surg* 3:59-60, 1987
 92. Summitt JK, Berghage TE: **Review of Diving Accident Reports, 1968**. US Navy Experimental Diving Unit Research Report 1 1-70, 1970
 93. Tengroh B, Epstein D, Fagerholm P, et al: Excimer laser photorefractive keratectomy for myopia. *Ophthalmology* 100:739-745, 1993
 94. Thalmann ED, Buckingham IP, Spaur WH: **Testing of Decompression Algorithms for Use in the US Navy Underwater Decompression Computer (Phase I)**. US Navy Experimental Diving Unit Report 1 1-80, 1980
 95. Thalmann ED: **Phase II Testing of Decompression Algorithms for Use in the US Navy Underwater Decompression Computer**. US Navy Experimental Diving Unit Report 1-84, 1984
 96. Thalmann ED: **Development of a Decompression Algorithm for Constant 0.7 ATA Oxygen Partial Pressure in Helium Diving**. US Navy Experimental Diving Unit Report 1-85, 1985
 97. Thalmann ED: **Air-N2O2 Decompression Algorithm Development**. US Navy Experimental Diving Unit Report 8-85, 1986
 98. Thorn SR, Clark JM: The toxicity of oxygen, carbon monoxide, and carbon dioxide, in Bove AA, Davis JC (eds): *Diving Medicine*. Philadelphia, WB Saunders, 1990, ed 2, pp 82-94
 99. Thorn SR (ed): **Hyperbaric Oxygen Therapy: A Committee Report**. Bethesda, Undersea and Hyperbaric Medical Society, 1992
 100. **US Navy Diving Manual**. Commander Naval Sea Systems Command Publication 0994-LP-001-9010. Washington, DC, US Government Press, 1993, Revision 3, Vol 1, pp 2-23 to 2-25
 101. *Ibid*, Chapter 8
 102. **US Navy Manual of the Medical Department**. Washington, DC, US Government Press, 1992, Change 107, pg 15-21
 103. *Ibid*, pp 15-38 to 15-51
 104. Van Buskirk EM, Cioffi GA: Glaucomatous optic neuropathy. *Am J Ophthalmol* 113:447-452, 1992
 105. Van Buskirk EM, Cioffi GA: Predicted outcome from hypotensive therapy for glaucomatous optic neuropathy. *Am J Ophthalmol* 116:636-640, 1993
 106. Van Der Aue O, Dufner G, Behnke A: The treatment of decompression sickness — an analysis of one hundred and thirteen cases. *J Industr Hyg Toxicol* 29:359-366, 1947
 107. Vann RD, Thalmann ED: Decompression physiology and practice, in Bennett PB, Elliott DH (eds): *The Physiology and Medicine of Diving*. London, WB Saunders, 1993, ed 4, pp 376-432
 108. Vogel R, Pitts R, Mills KB, et al: Effect of timolol versus pilocarpine on visual field progression in patients with primary open-angle glaucoma. *Ophthalmology* 99: 1505-1511, 1992
 109. Waring GO, Lynn MJ, Culbertson W, et al: Three year results of the prospective evaluation of radial keratotomy (PERK) study. *Ophthalmology* 95:1339-1354, 1987
 110. Waring GO, Lynn M, Nizam A, et al: Results of the prospective evaluation of radial keratotomy (PERK) study five years after surgery. *Ophthalmology* 98: 1164-1176, 1991
 111. Westman G, Christianson R, Egstrom G: Visual fields of the SCUBA diver. *Human Factors* 7:423-430, 1965
 112. Wilmshurst P: retinal changes, gas bubbles, and diving (letter). *Lancet* 438, 1989
 113. Wright WL: SCUBA divers' delayed toxic epithelial keratopathy from commercial mask defogging agents. *Am J Ophthalmol* 93:470-472, 1982
 114. Yap CL: Delayed decompression sickness — the Singapore experience, in *Proc Joint S Pacific Underwater Med Soc and Republic Singapore Navy Underwater Med Conf. SPUMS J Suppl*, 1981
 115. Yohai RA, Bullock JD, Aziz AA, Markert RJ: Survival

factors in rhino-orbital-cerebral mucormycosis. *Surv Ophthalmol* 39:3-22, 1994

Outline

- I. Hyperbaric terminology and physics
- II. Types of hyperbaric exposures
- III. Underwater optics
 - A. Light attenuation
 - B. Color perception
 - C. Refractive changes
 - D. Visual field
- IV. Underwater refractive correction
 - A. Contact lenses
 - B. Corrective face mask lenses
- V. Ocular barotrauma
- VI. Decompression sickness
 - A. Pathophysiology
 - B. Systemic manifestations
 - C. Ophthalmic manifestations
 - D. Treatment
- VII. Arterial gas embolism
 - A. Pathophysiology
 - B. Systemic manifestations
 - C. Ophthalmic manifestations
 - D. Treatment
- VIII. Other causes of decreased vision after diving
- IX. Central nervous system oxygen toxicity
 - A. Pathophysiology
 - B. Systemic manifestations
 - C. Ophthalmic manifestations
 - D. Treatment
- X. Other ophthalmic effects of hyperbaric oxygen
- XI. Hyperbaric oxygen therapy for ocular disorders
 - A. Cystoid macular edema
 - B. Radiation-induced optic neuropathy
 - C. Central retinal artery occlusion
 - D. Rhino-orbital-cerebral mucormycosis
 - E. UHMS recommended indications
- XII. Diving after eye surgery
 - A. Corneal surgery
 - B. Cataract surgery
 - C. Vitreoretinal surgery
 - D. Glaucoma filtering surgery
 - E. Corneoscleral suture removal
 - F. Other surgery
- XIII. Ophthalmic considerations in fitness to dive evaluations
 - A. Visual acuity
 - B. Color vision
 - C. Corneal and cataract surgery
 - D. Enucleation
 - E. Glaucoma
 - F. Vitreoretinal disorders
 - G. Visual residua from decompression sickness or gas embolism
 - H. Miscellaneous
- XIV. Ocular medications and diving
 - A. Topical beta-blockers
 - B. Pilocarpine
 - C. Dipivefrin
 - D. Carbonic anhydrase inhibitors
 - E. Topical steroids
 - F. Topical antibiotics and anti-viral agents
- XV. Miscellaneous ocular problems

The author wishes to express his appreciation to the following ophthalmologists, diving medical officers, and hyperbaric physiologists whose council and expertise were invaluable in the preparation of this manuscript: Dr. Van Aldred, Dr. Banks Anderson, Dr. Peter Bennett, Dr. Steven Chalfin, CDR Clint Fletcher, Dr. Ed Galbavy, Dr. David Harris, CAPT Marie Knafelc, Dr. Tim Peterson, CAPT Hank Schwartz, and Dr. Richard Vann.

The opinions expressed in this paper are those of the author and do not necessarily reflect the opinions or the policies of the Department of the Navy or the Department of Defense.

Reprint address: CAPT Frank K. Butler, Jr., M.D., Department of Ophthalmology, Naval Hospital, Pensacola FL 32512.